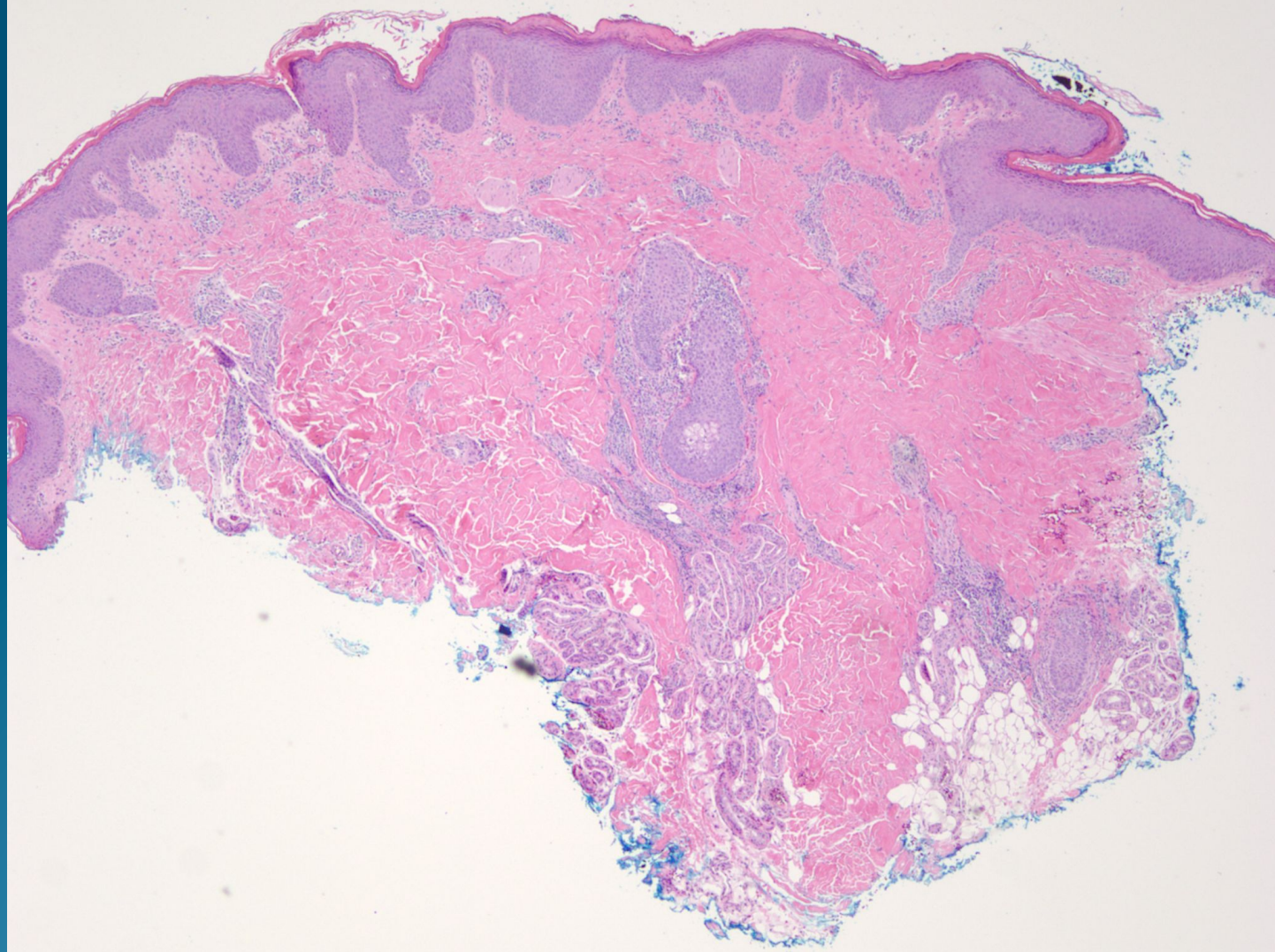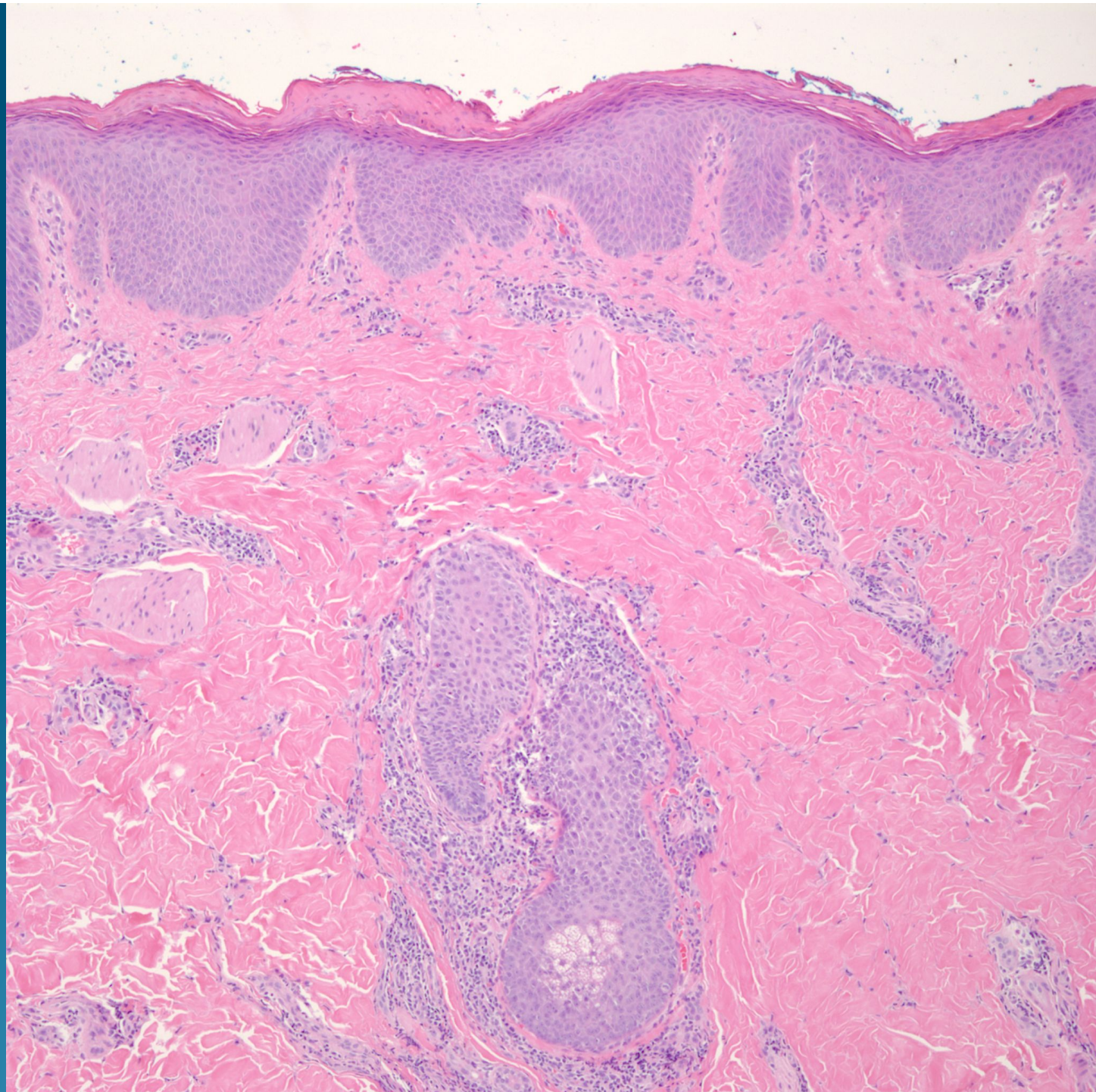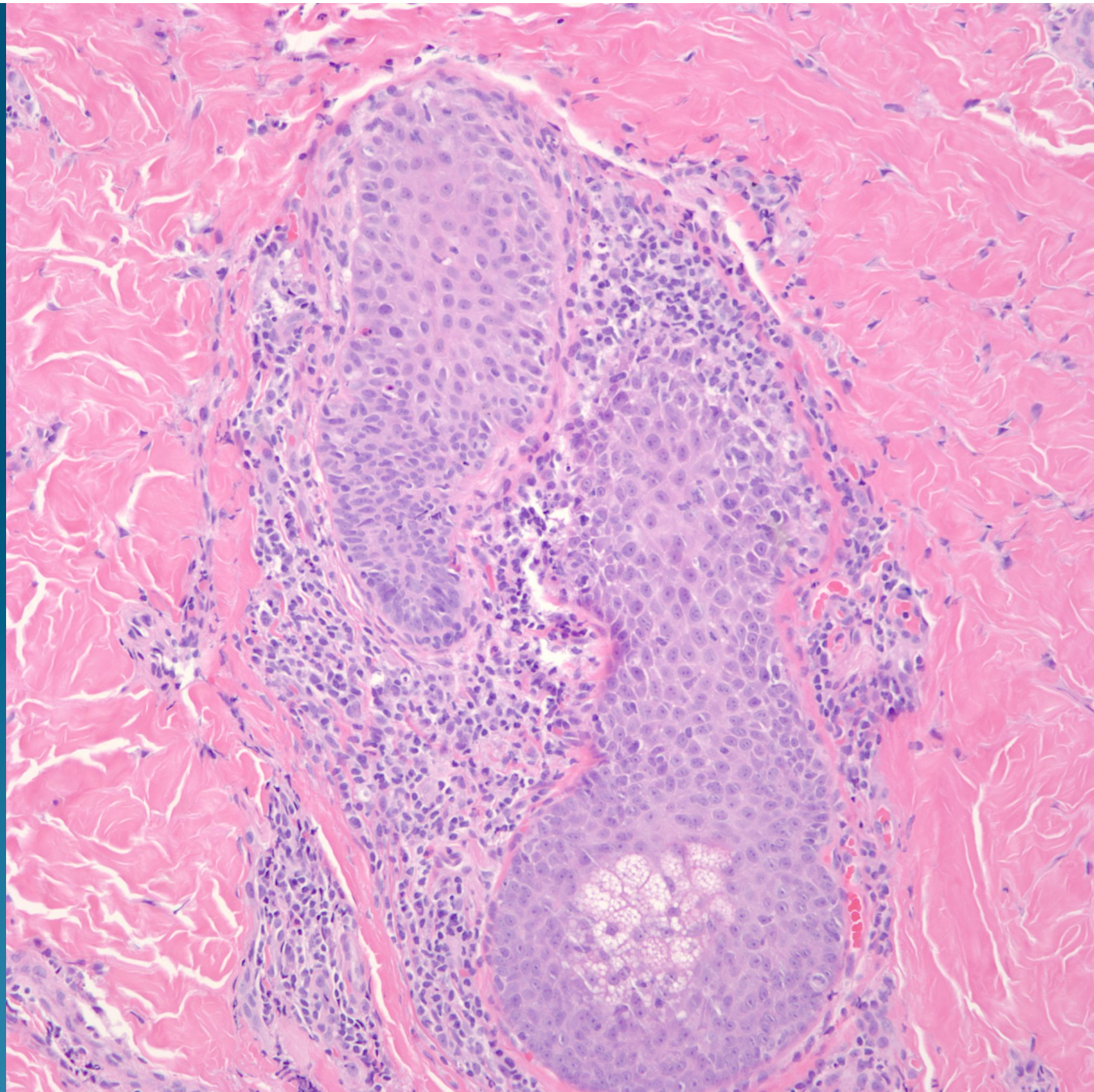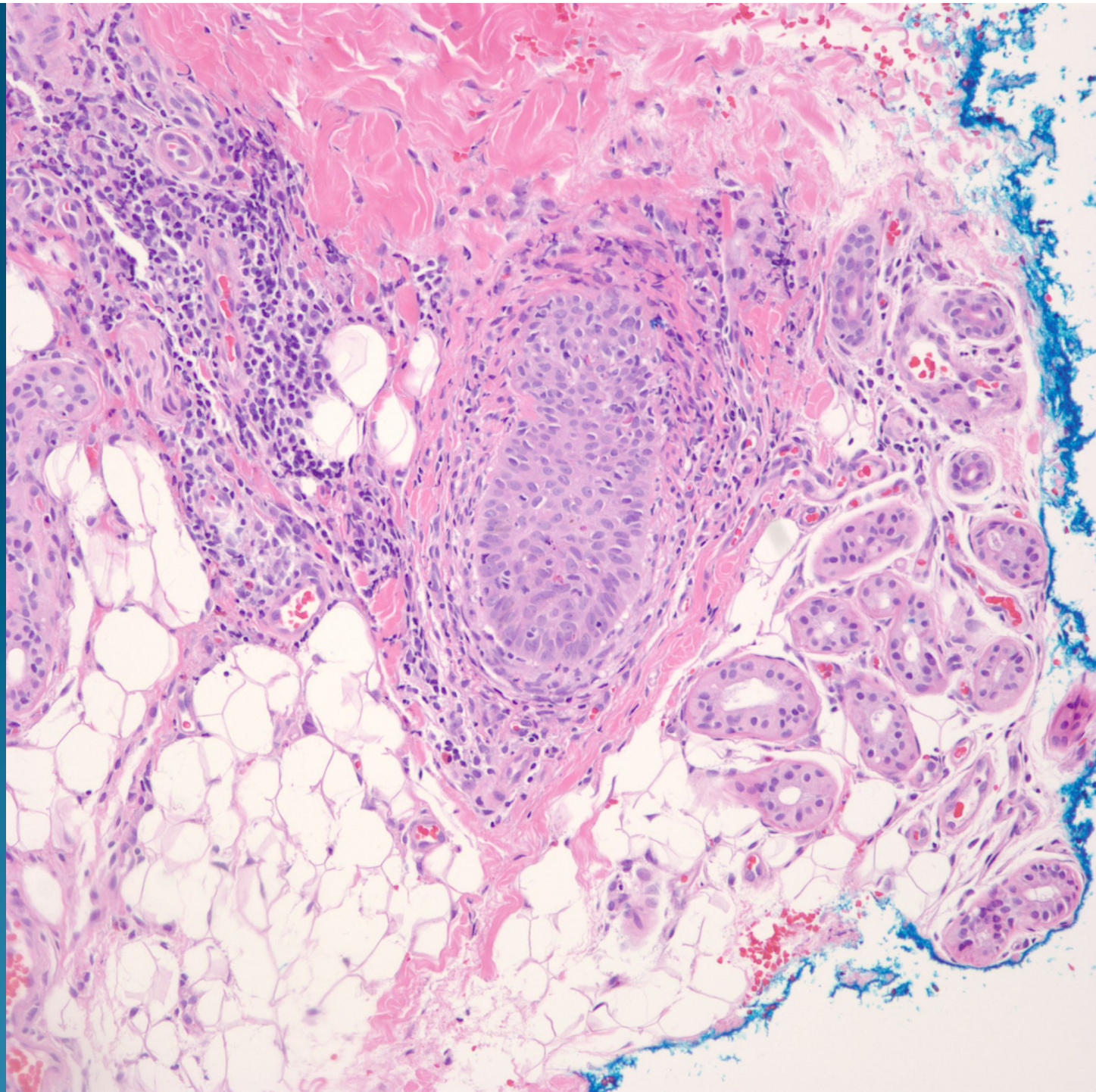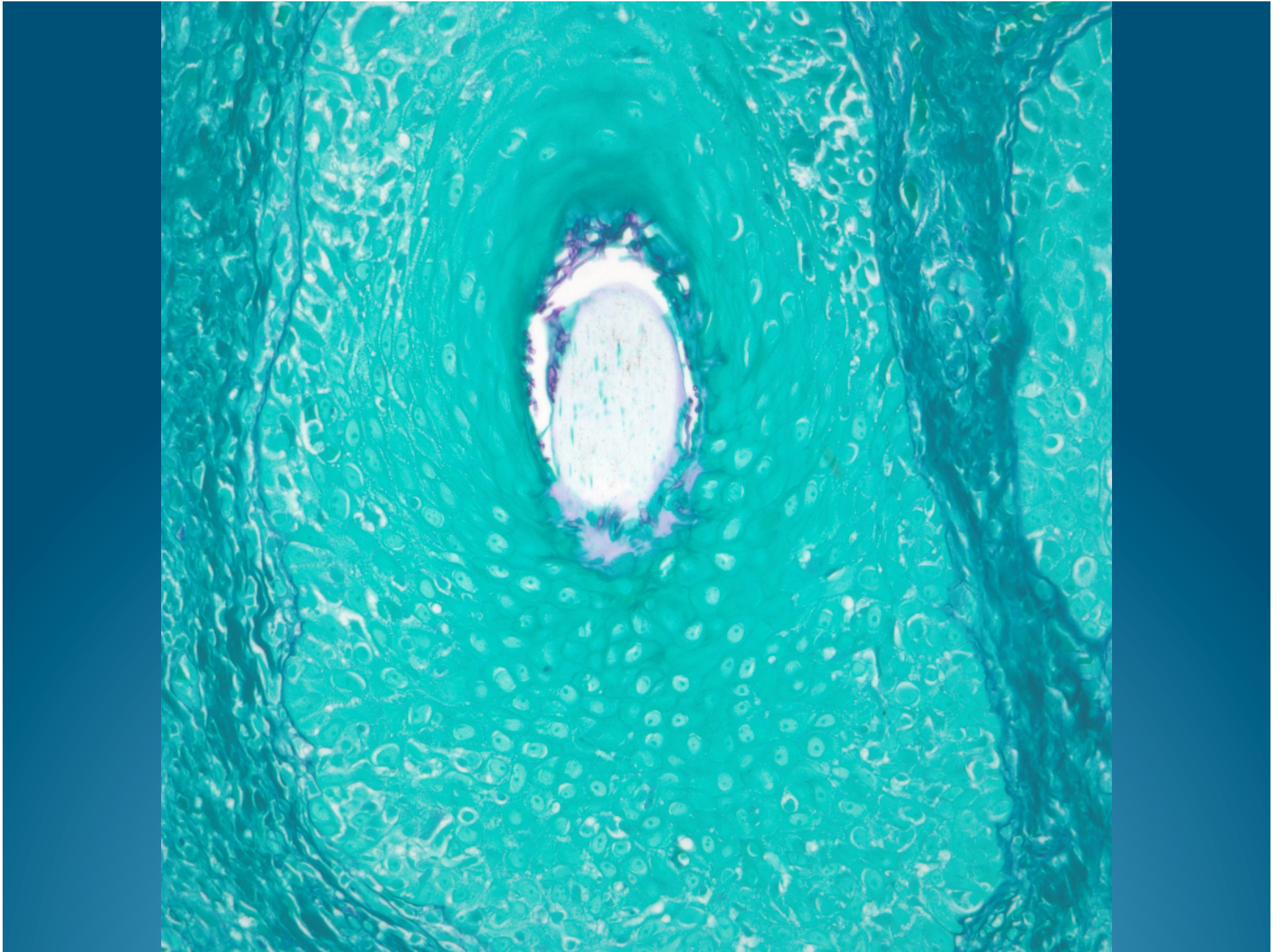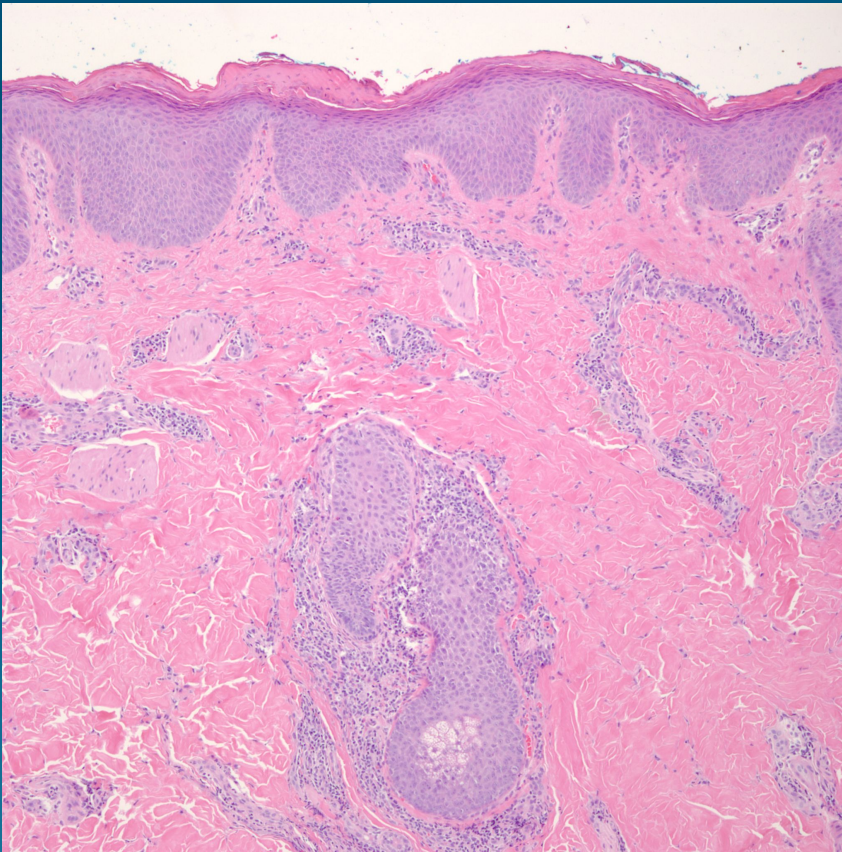


# Dermatophyte with Endothrix Infection



# Pearls



- Dermatophyte infection may mimic nearly every non-infectious dermatitis-must have high level of suspicion
- Consider when intracorneal neutrophils or suppurative folliculitis
- Confirm with PAS/GMS for fungus